

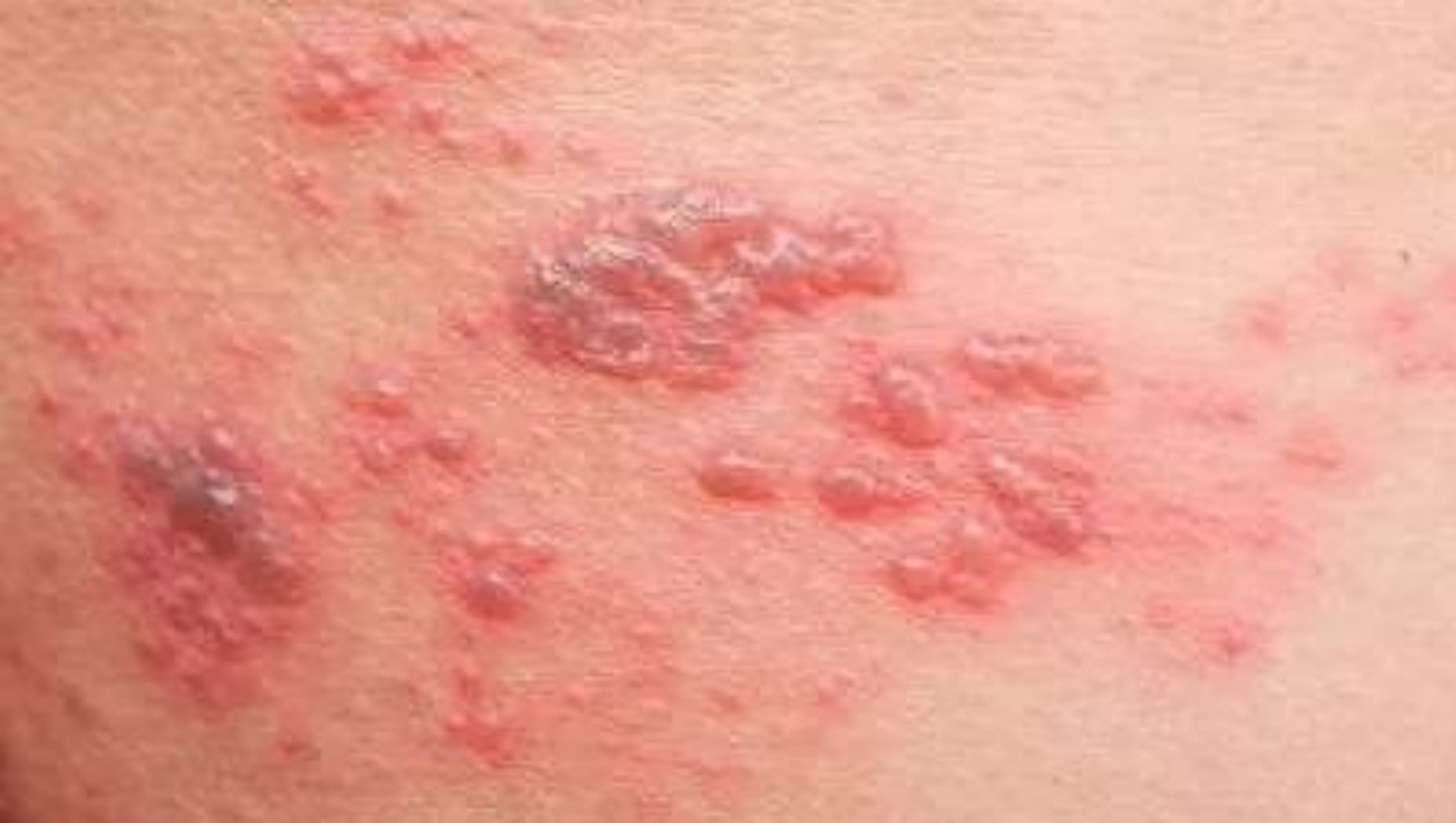

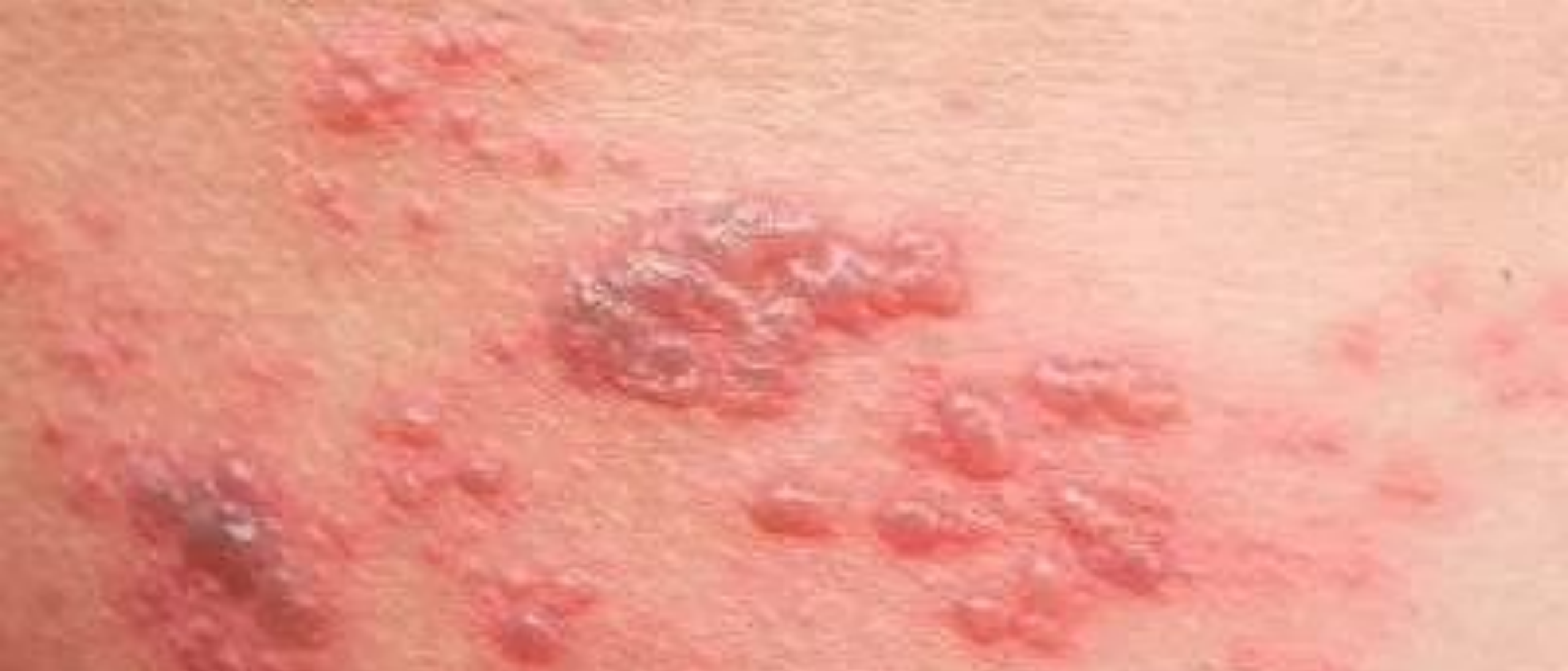**SOUTH AFRICAN
WRESTLING FEDERATION
HSS COUNCIL**

Skin Conditions in Wrestling

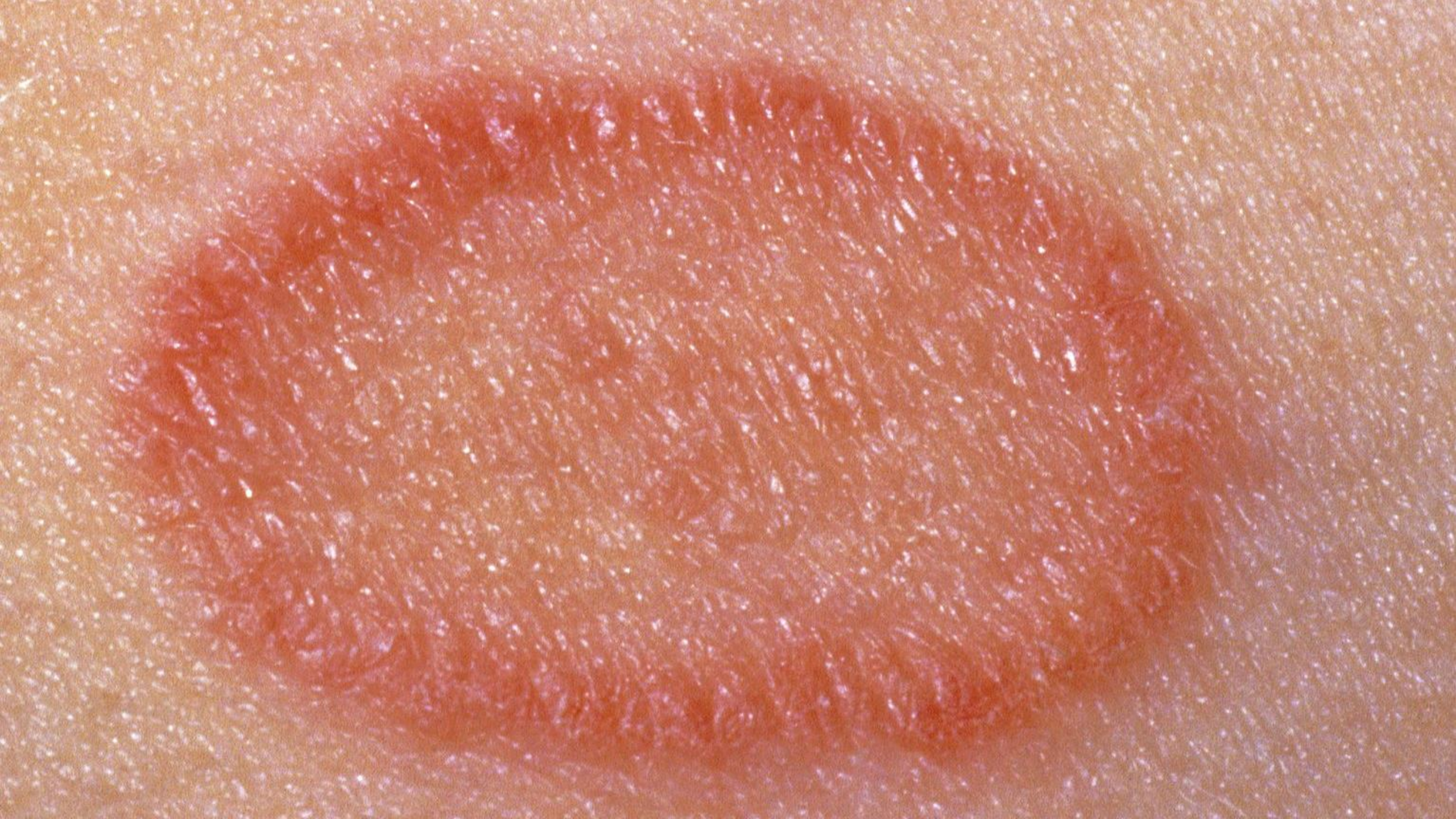Dr WAP von Ludwig

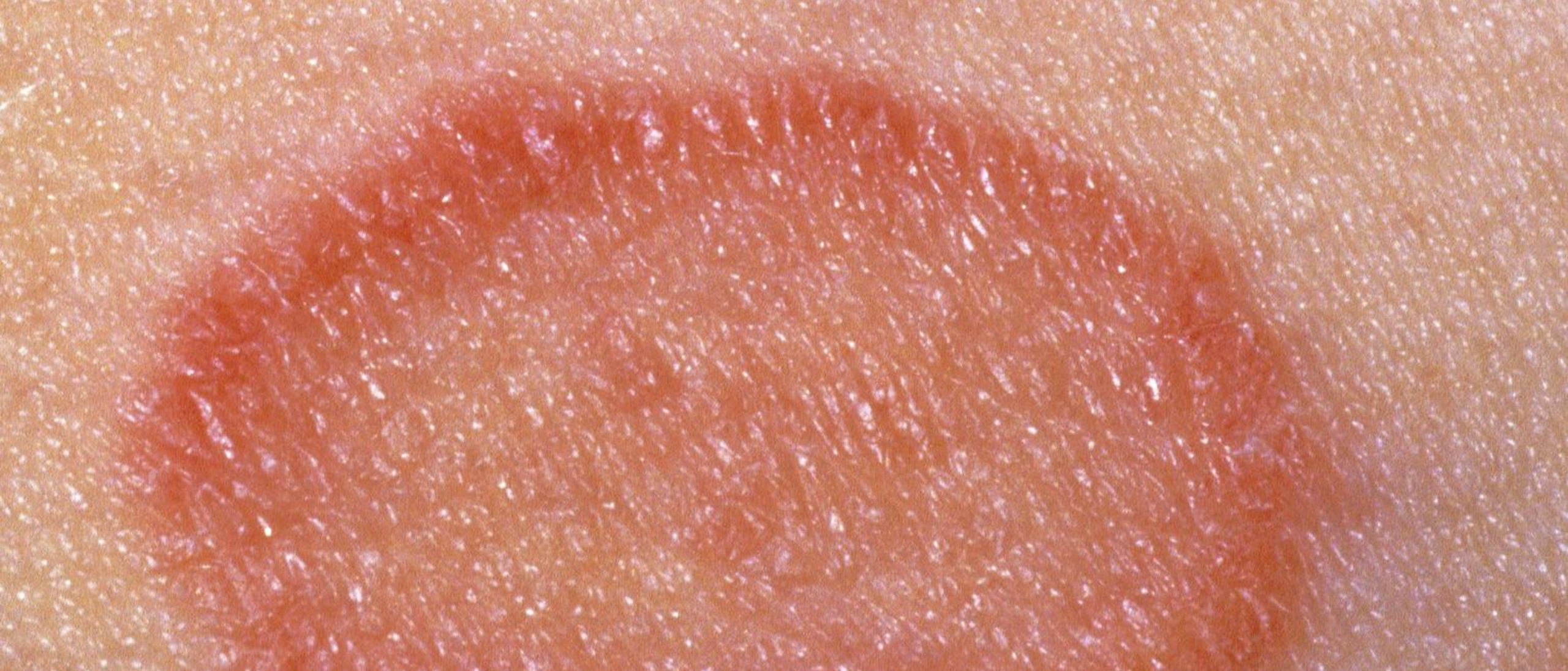All rights reserved. No part of this document shall be reproduced, stored in a retrieval system, or transmitted by any means, electronically, mechanically, by photocopying, recoding or otherwise, without the written permission of the owner. No patent liability is assumed with respect to the use of the information contained in this manual. The document designer assumes no responsibility for losses of any kind resulting from the direct or indirect use of the information contained herein. It is not permitted to use this manual document for resale in the capacity of a publisher, creator, or distributor of learning material without the consent of the originator.



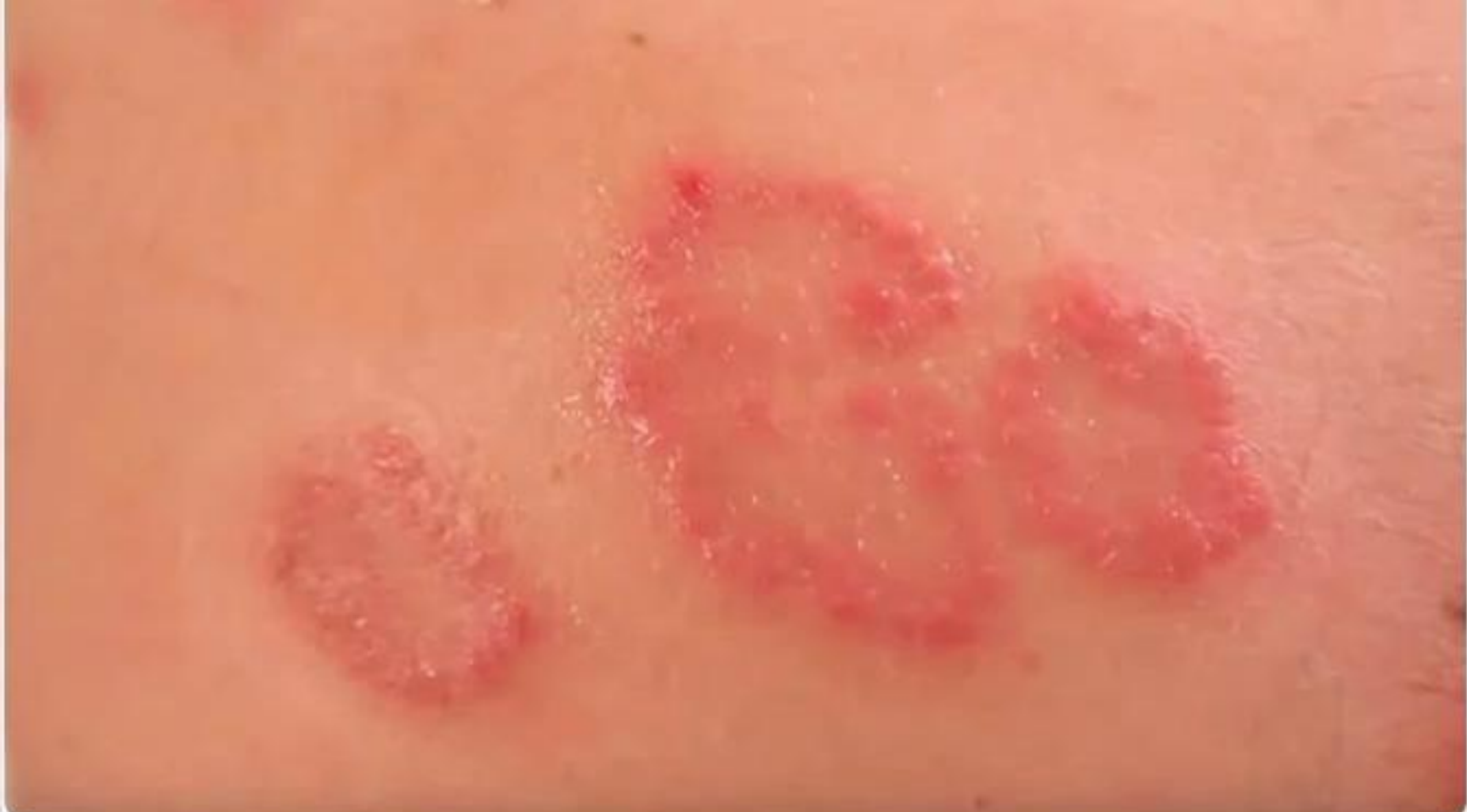

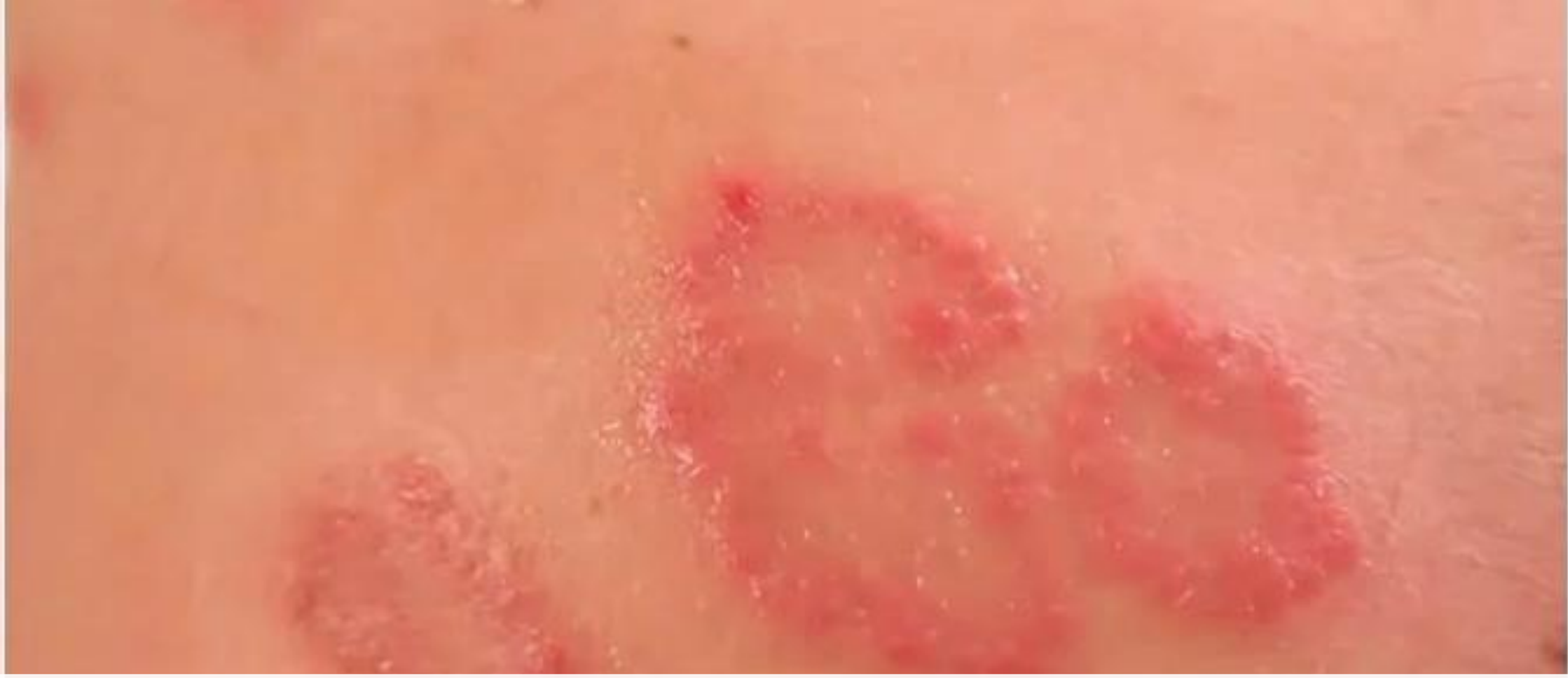Shingles






"HERALD PATCH" - Pityriasis Rosea





Nummular Eczema



When you hear
hoofbeats,
think of
horses...

Common
conditions occur
commonly

Ringworm

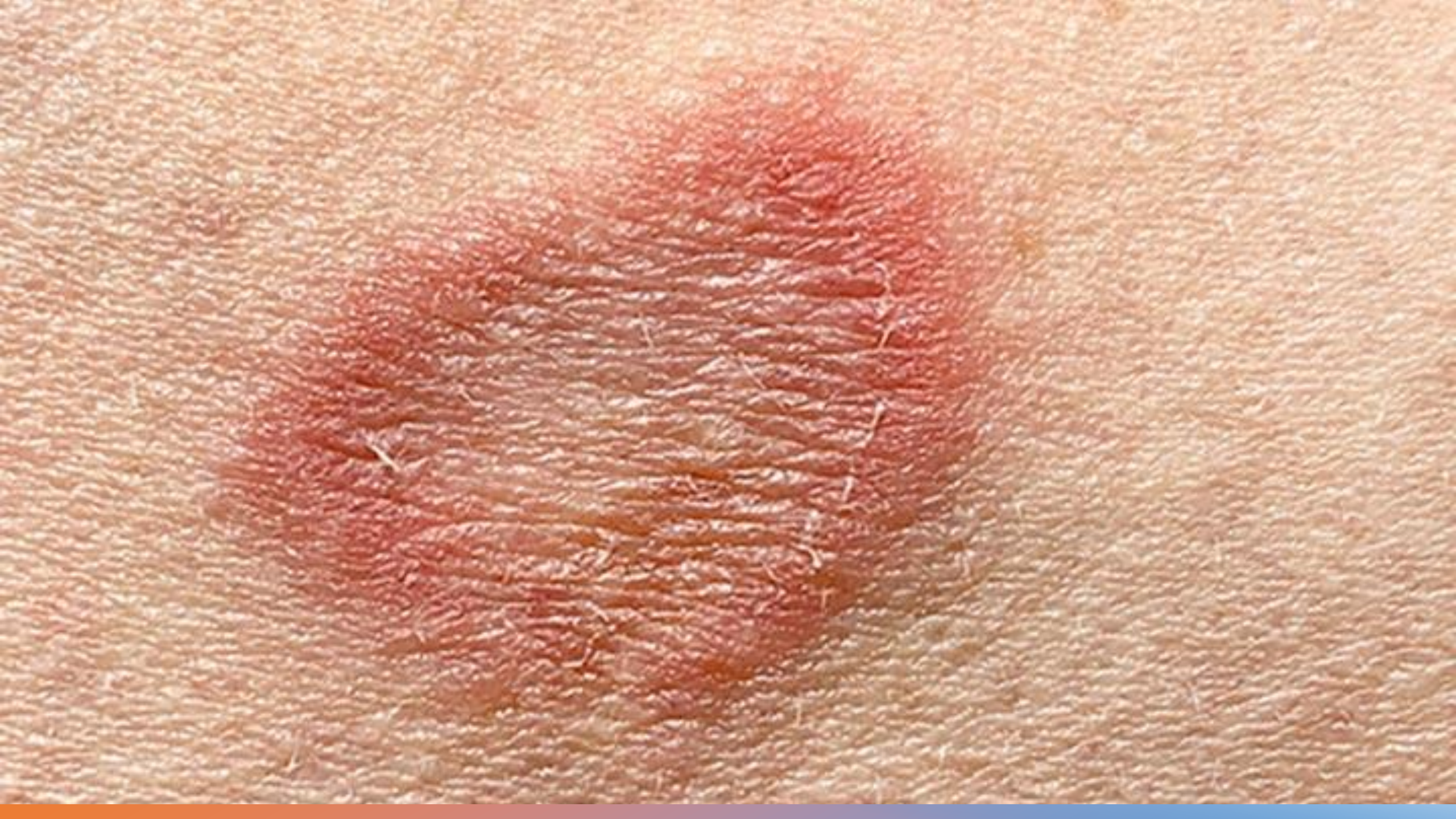Impetigo

Molluscum Contagiosum

Herpes Gladiatorum

Common
conditions occur
commonly

Ringworm





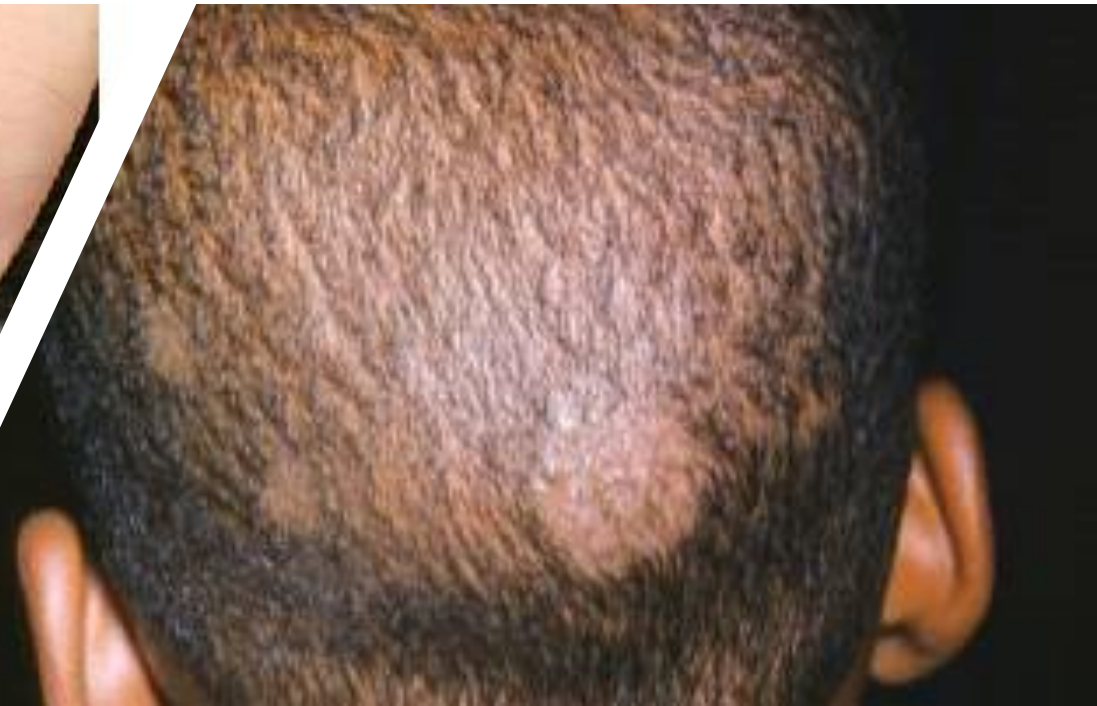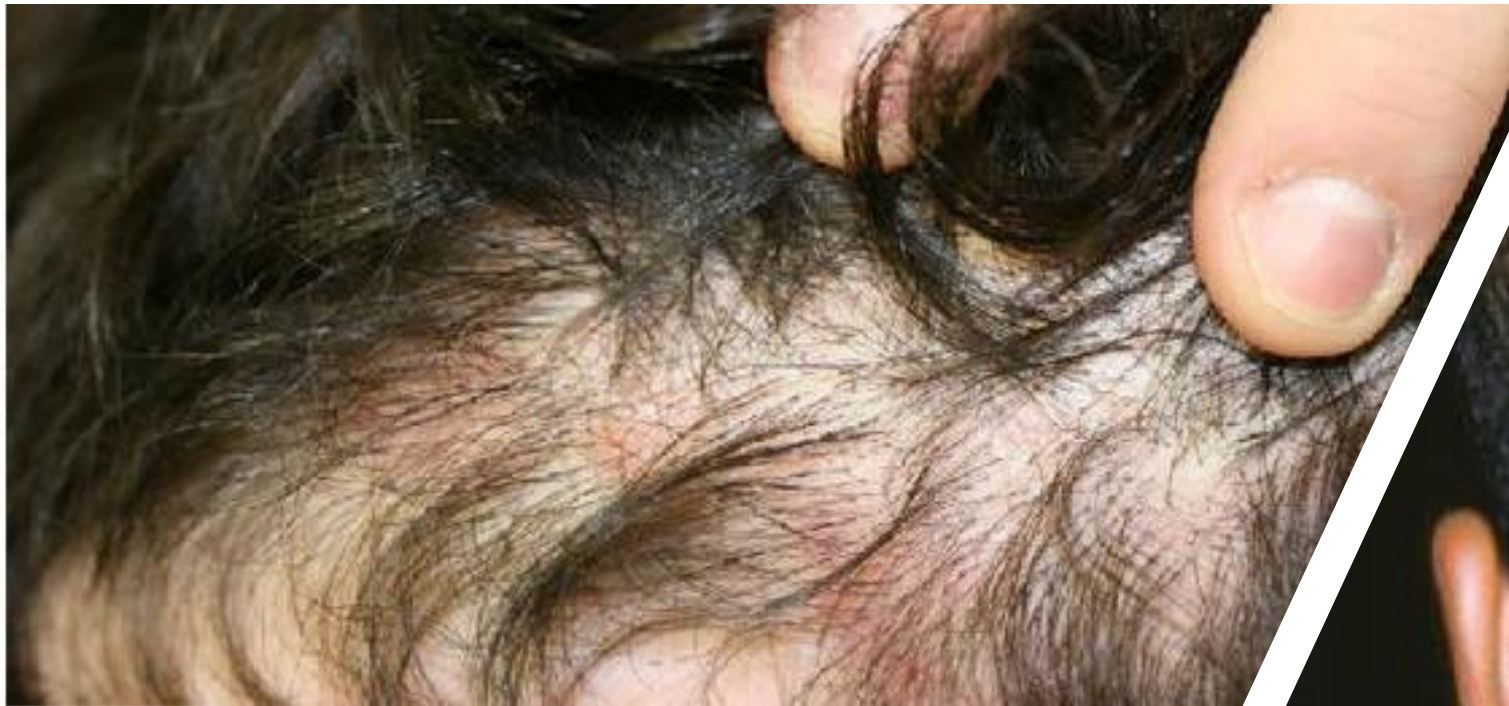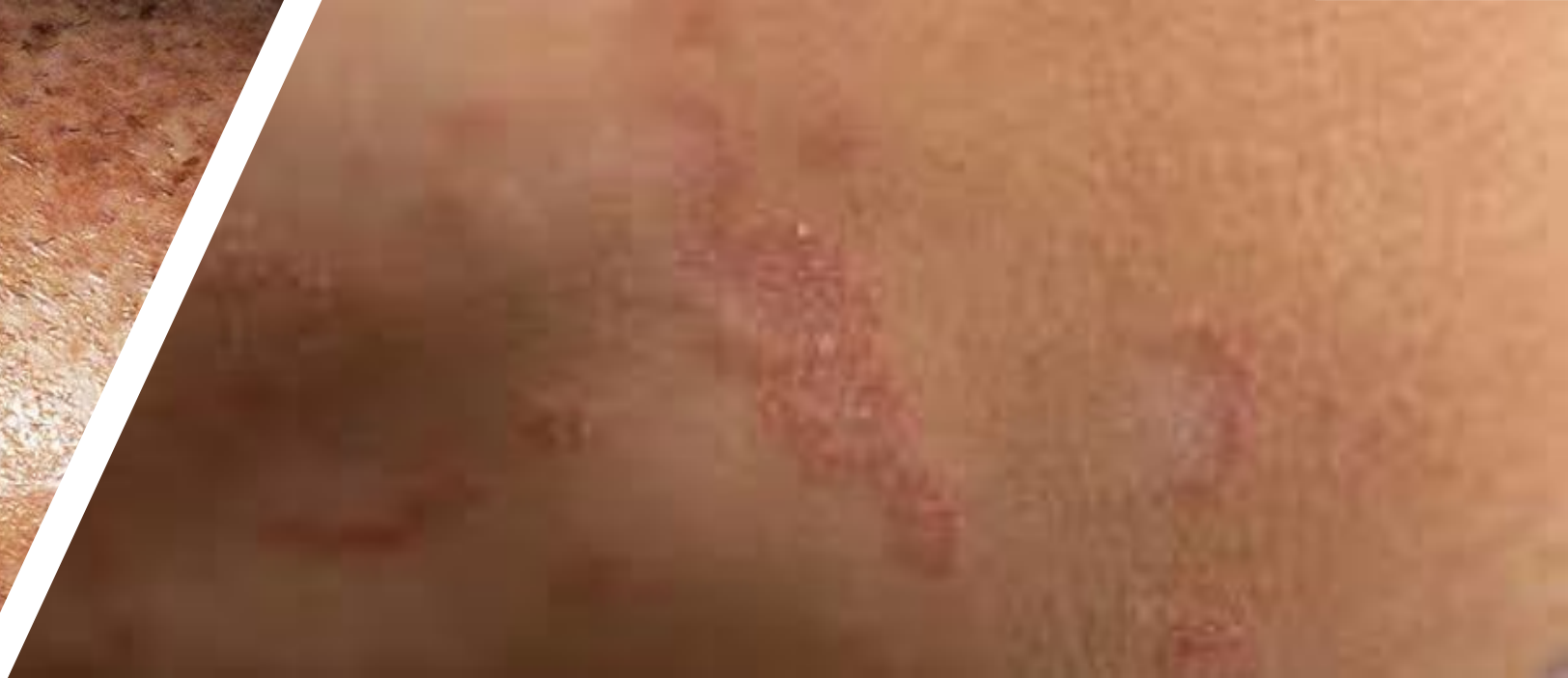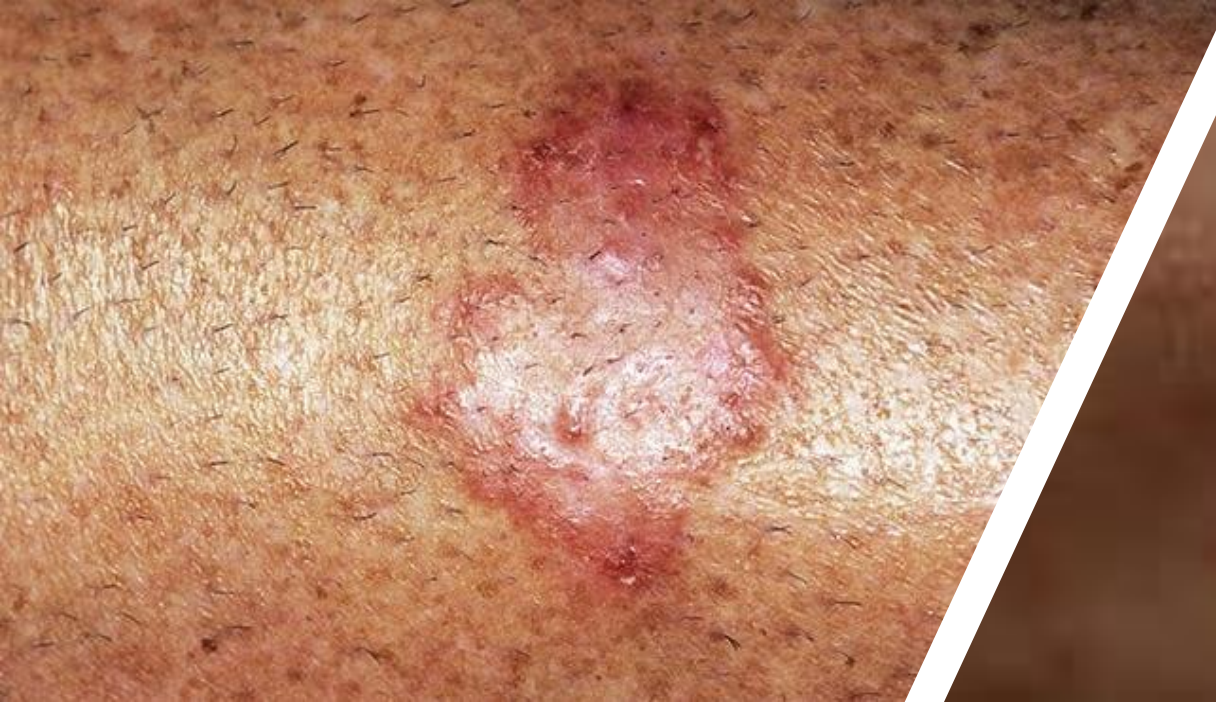Asymptomatic carriers

- 50% of affected communities are carriers (South African study)
- No symptoms at all
- Hair acts as a reservoir for spores
- Keep this in mind when we set policies and guidelines



THE ROLE OF WRESTLING MATS...

- Controversial
- Results from studies are conflicting
- Lower body vs upper body
- Clean mats to prevent:
 - Bacterial infections (like Impetigo)
 - Viral infections (like Hepatitis)



TREATMENT

- **Tinea Gladiatorum distinct from Capitis (head) and Corporis (body)**
- **Should be treated more aggressively**
- **Low threshold for oral treatment**
- **Get local doctor on board**
- **Return to wrestling after 48 hours on treatment**
- **? 1 week for lesions on scalp ?**

Current SAWF competition guidelines

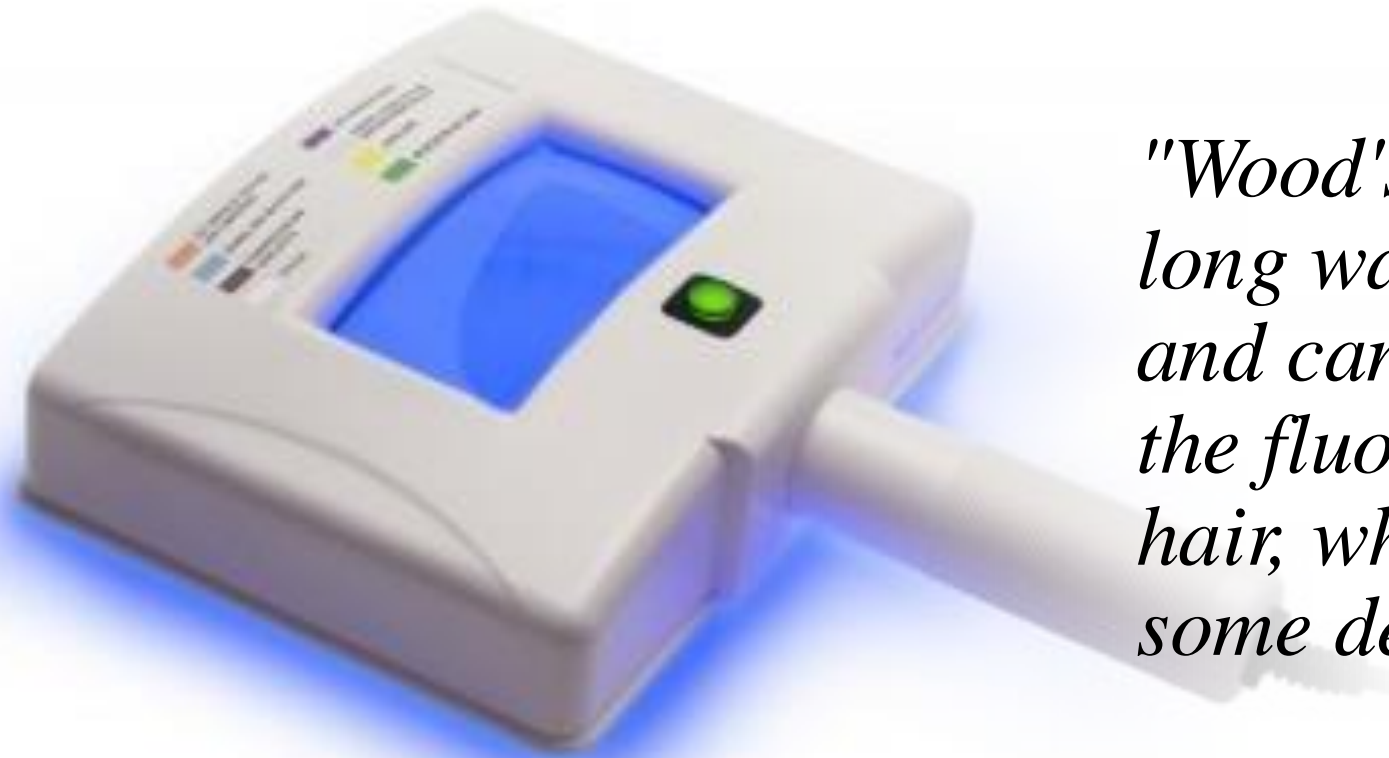- Strap if on the body
- Do not wrestle if on the head
- Letter from dermatologist

Suggested approach:

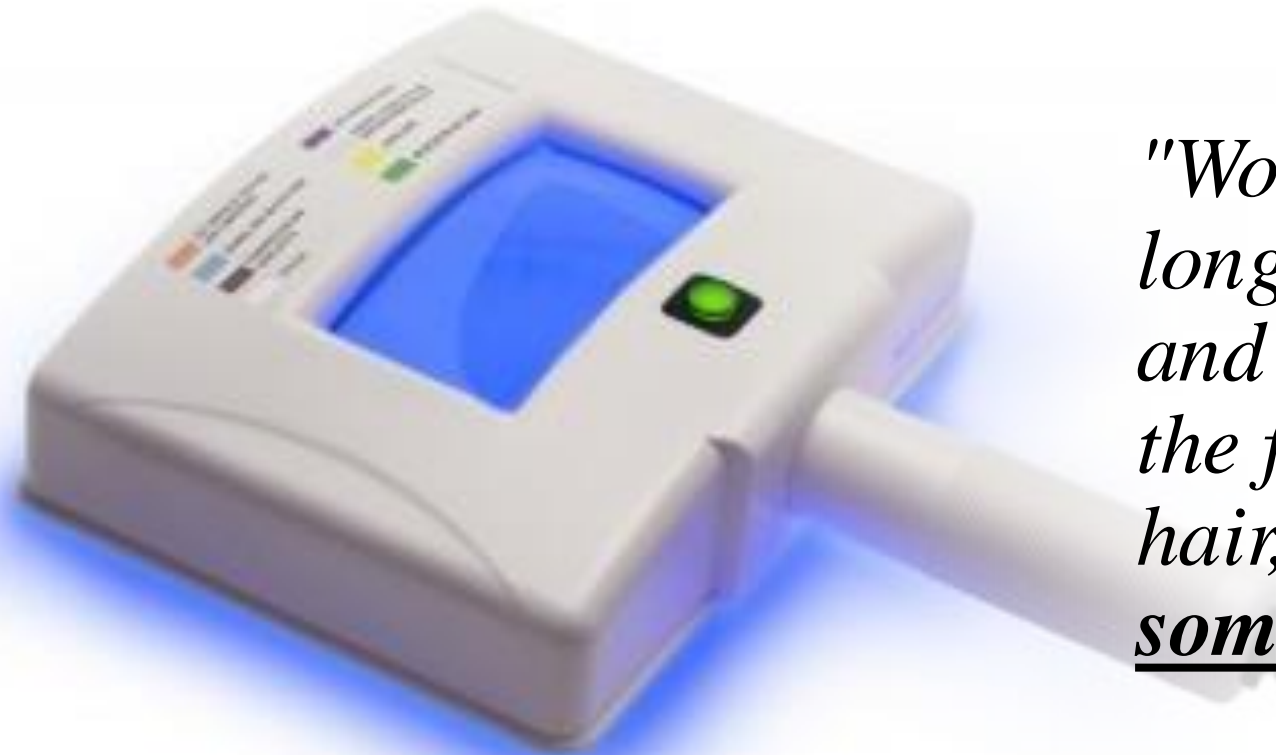- **Body** – Wrestler can compete if a medical certificate is presented that confirms ongoing treatment for at least 48-72 hours.
- **Scalp** – Wrestler can compete if a medical certificate is presented that confirms ongoing treatment for at least 14 days.



Wood's lamp



"Wood's lamp is a source of long wave ultraviolet light and can be used to detect the fluorescence in skin and hair, which is a feature of some dermatophytes."



"Wood's lamp is a source of long wave ultraviolet light and can be used to detect the fluorescence in skin and hair, which is a feature of some dermatophytes."


some dermatophytes:


Dermatophyte Genera	Dermatophyte Species
<i>Trichophyton</i>	<i>Trichophyton violaceum</i> <i>Trichophyton mentagrophyte</i> <i>Trichophyton rubrum</i> <i>Trichophyton interdigitale</i> <i>Trichophyton tonsurans</i> <i>Trichophyton soudanese</i> <i>Trichophyton verrucosum</i>
<i>Microsporum</i>	<i>Microsporum canis</i> <i>Microsporum ferrugineum</i>
<i>Epidermophyton</i>	<i>Epidermophyton floccosum</i>

some dermatophytes:

Dermatophyte Genera	Dermatophyte Species
<i>Trichophyton</i>	<i>Trichophyton violaceum</i> <i>Trichophyton mentagrophyte</i> <i>Trichophyton rubrum</i> <i>Trichophyton interdigitale</i> <i>Trichophyton tonsurans</i> <i>Trichophyton soudanese</i>
<i>Microsporum</i>	<i>Trichophyton verrucosum</i> <i>Microsporum canis</i> <i>Microsporum ferrugineum</i>
<i>Epidermophyton</i>	<i>Epidermophyton floccosum</i>

some dermatophytes: *wrestling*

Dermatophyte Genera	Dermatophyte Species
<i>Trichophyton</i>	 <i>Trichophyton violaceum</i> <i>Trichophyton mentagrophyte</i> <i>Trichophyton rubrum</i> <i>Trichophyton interdigitale</i> <i>Trichophyton tonsurans</i> <i>Trichophyton soudanese</i>
<i>Microsporum</i>	<i>Trichophyton verrucosum</i> <i>Microsporum canis</i> <i>Microsporum ferrugineum</i>
<i>Epidermophyton</i>	<i>Epidermophyton floccosum</i>



Common
conditions occur
commonly

Ringworm

Impetigo

Molluscum Contagiosum

Herpes Gladiatorum

Common
conditions occur
commonly

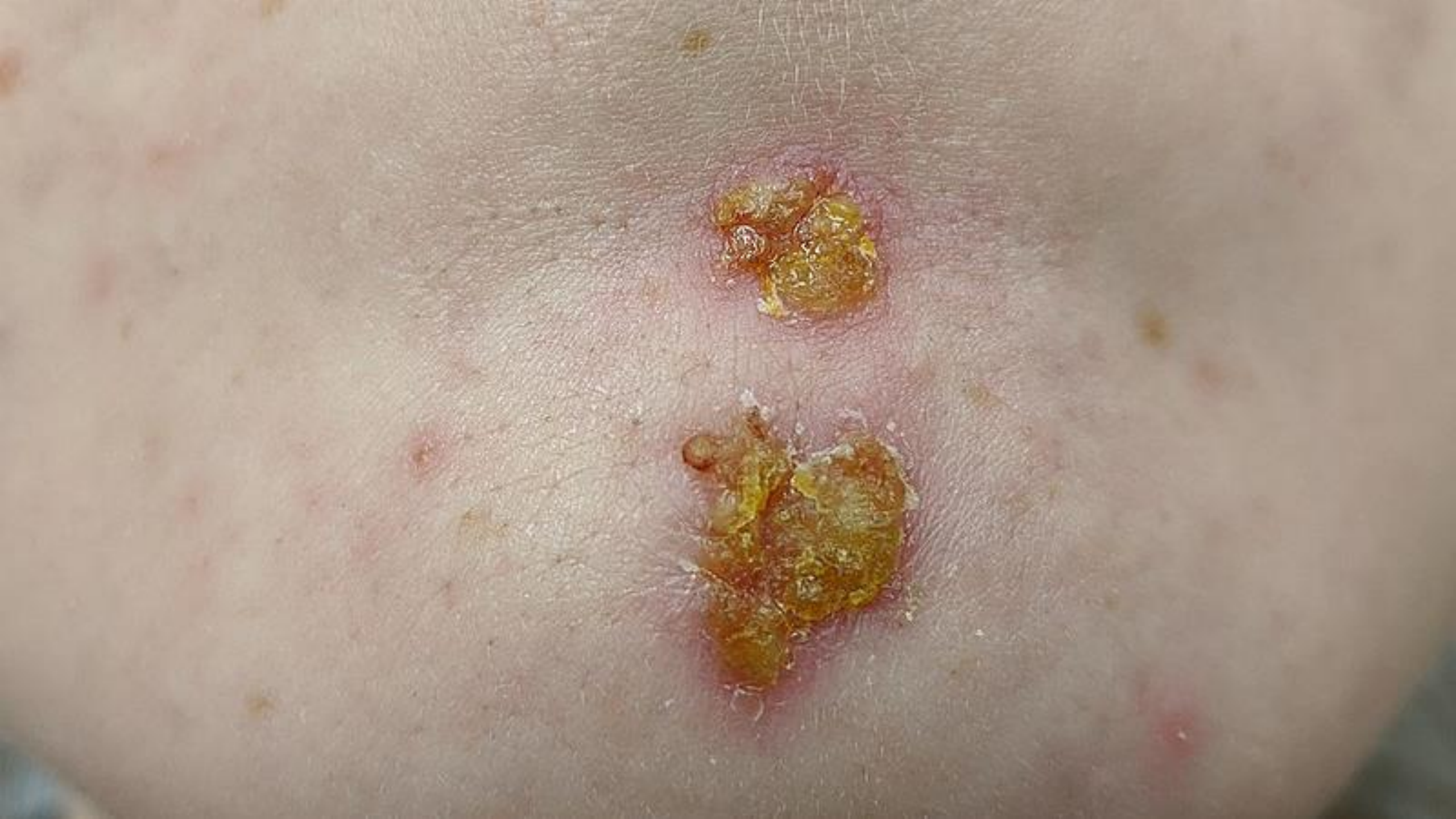Impetigo

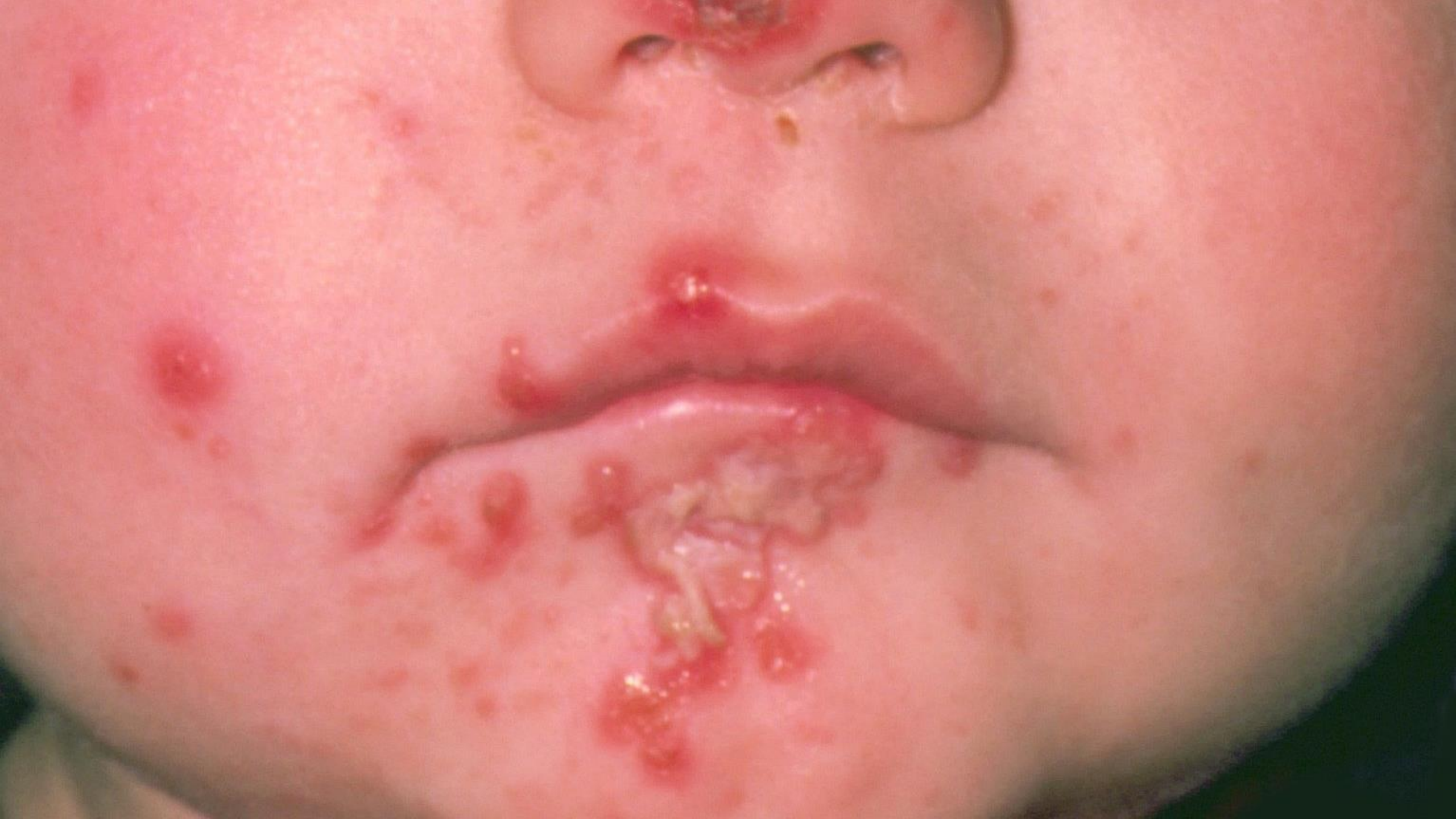Impetigo

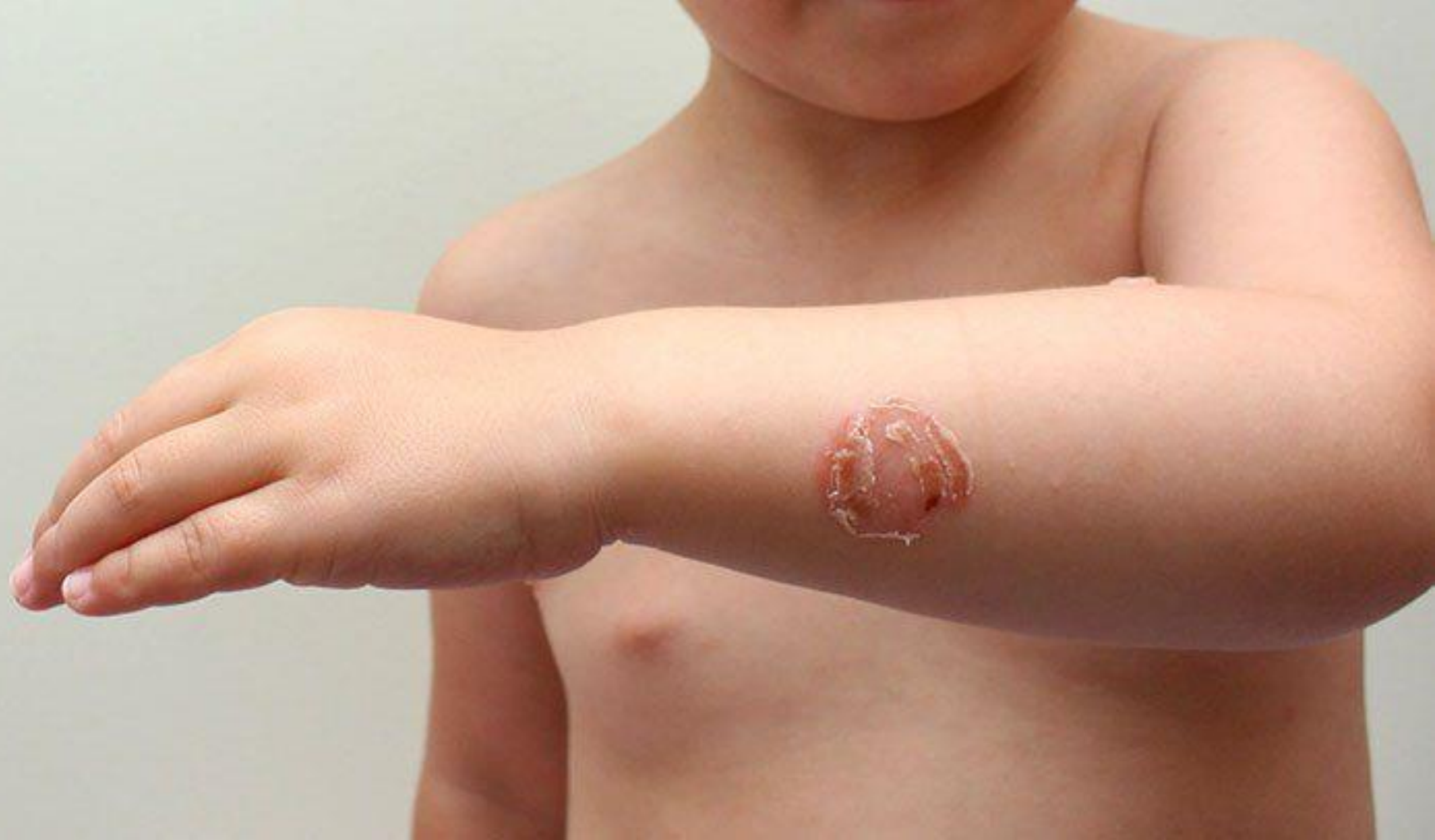- The **NASTY** one!
- Bacterial infection
- Extremely contagious
 - Several lesions
 - Mat surface
- *"The scab that doesn't heal"*

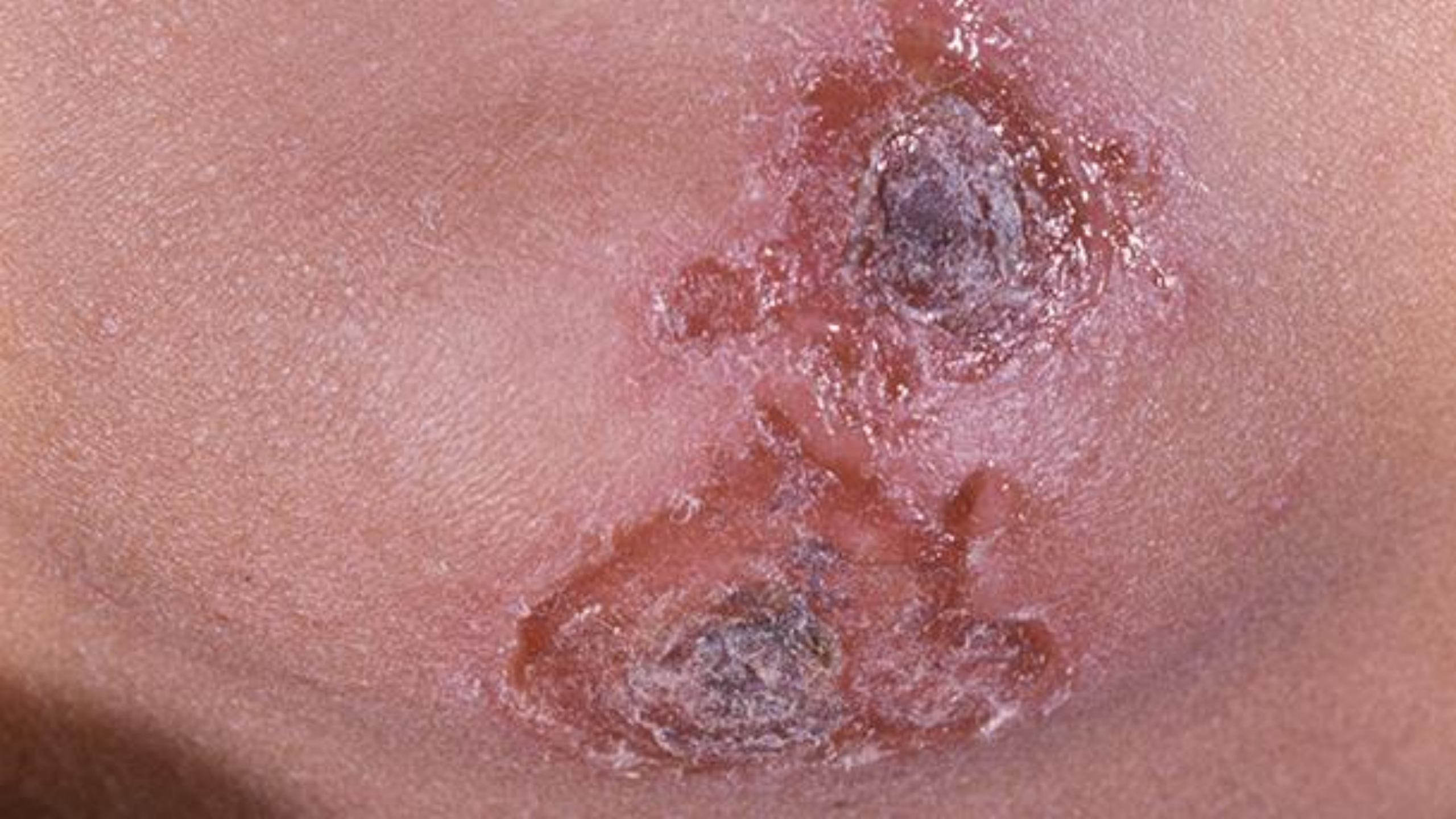


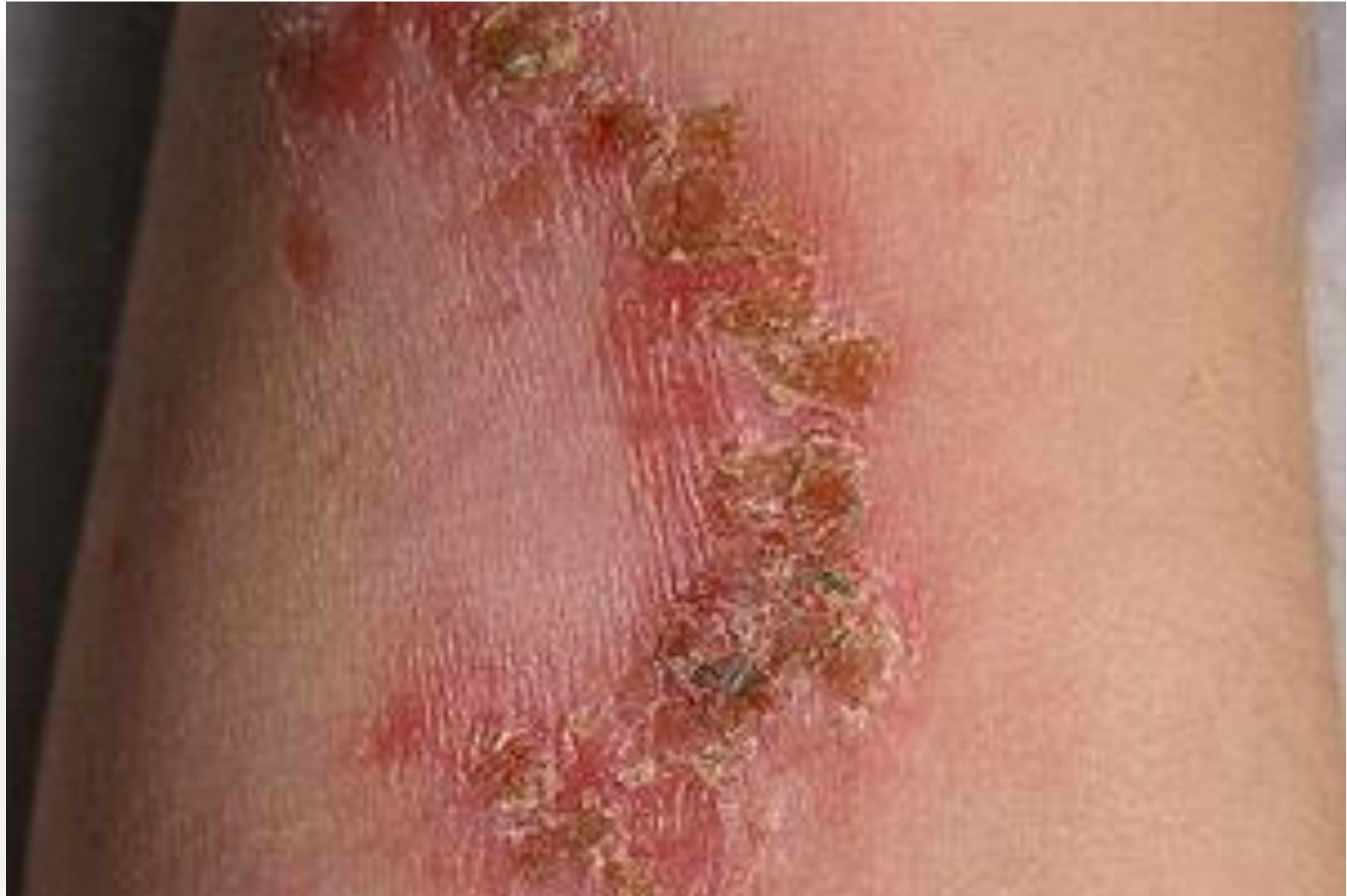











Management

- Do not wrestle
- Needs antibiotic (oral) treatment
- Not only cream
- Watch out for combination creams!

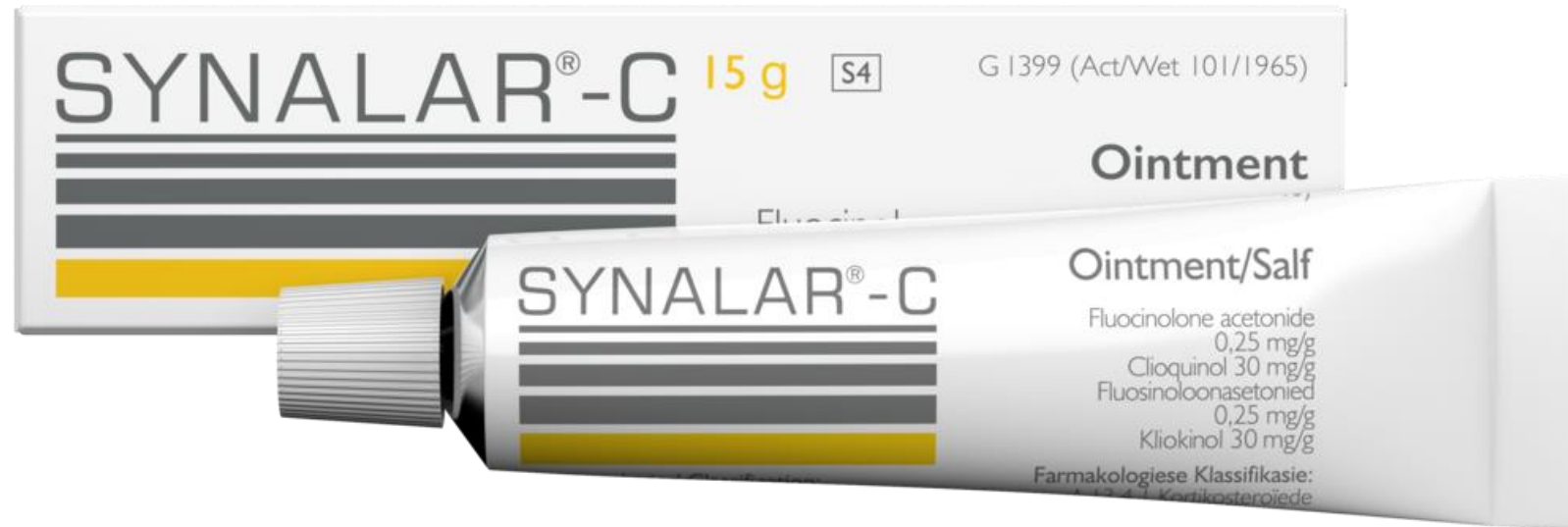Combination creams

- Preferred by pharmacists
- No purpose
- Makes diagnosis difficult
- Make infective skin conditions worse
- Cortisone causes initial improvement



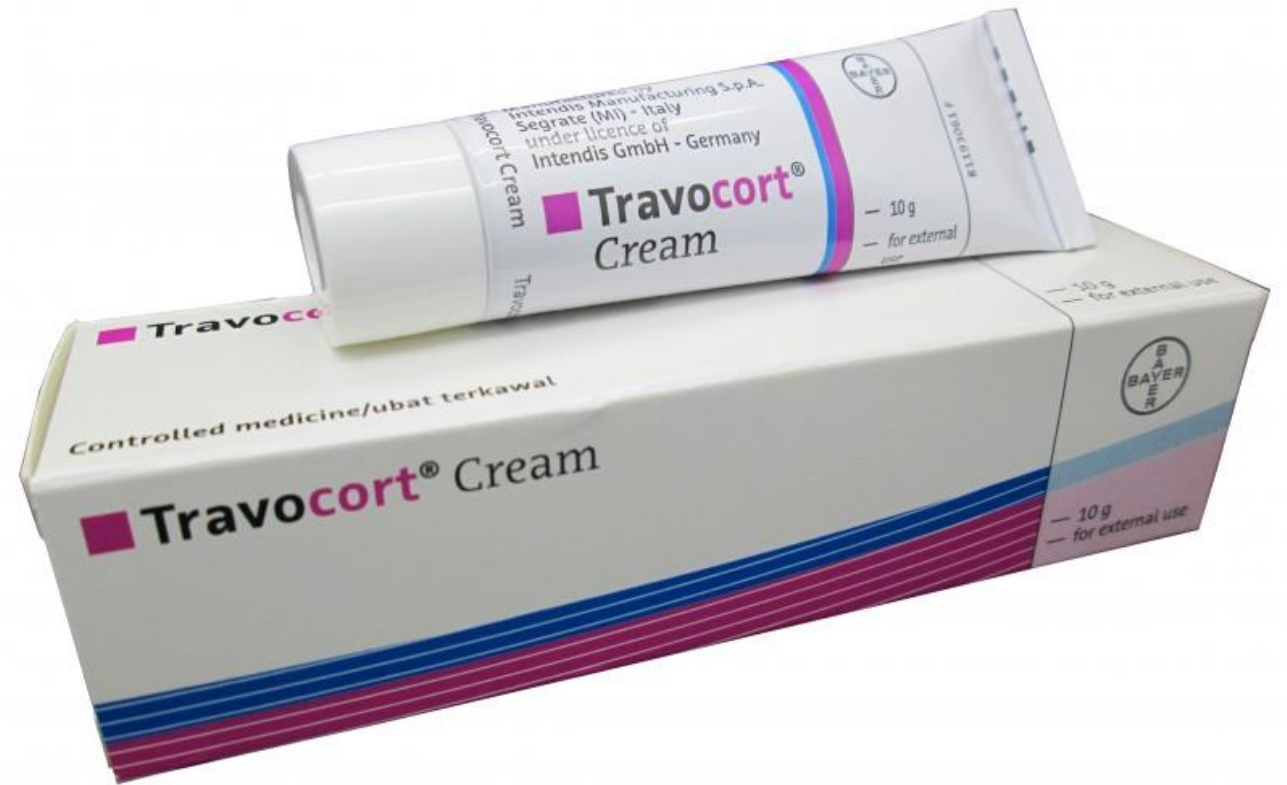Combination creams

- Preferred by pharmacists
- No purpose
- Makes diagnosis difficult
- Make infective skin conditions worse
- Cortisone causes initial improvement



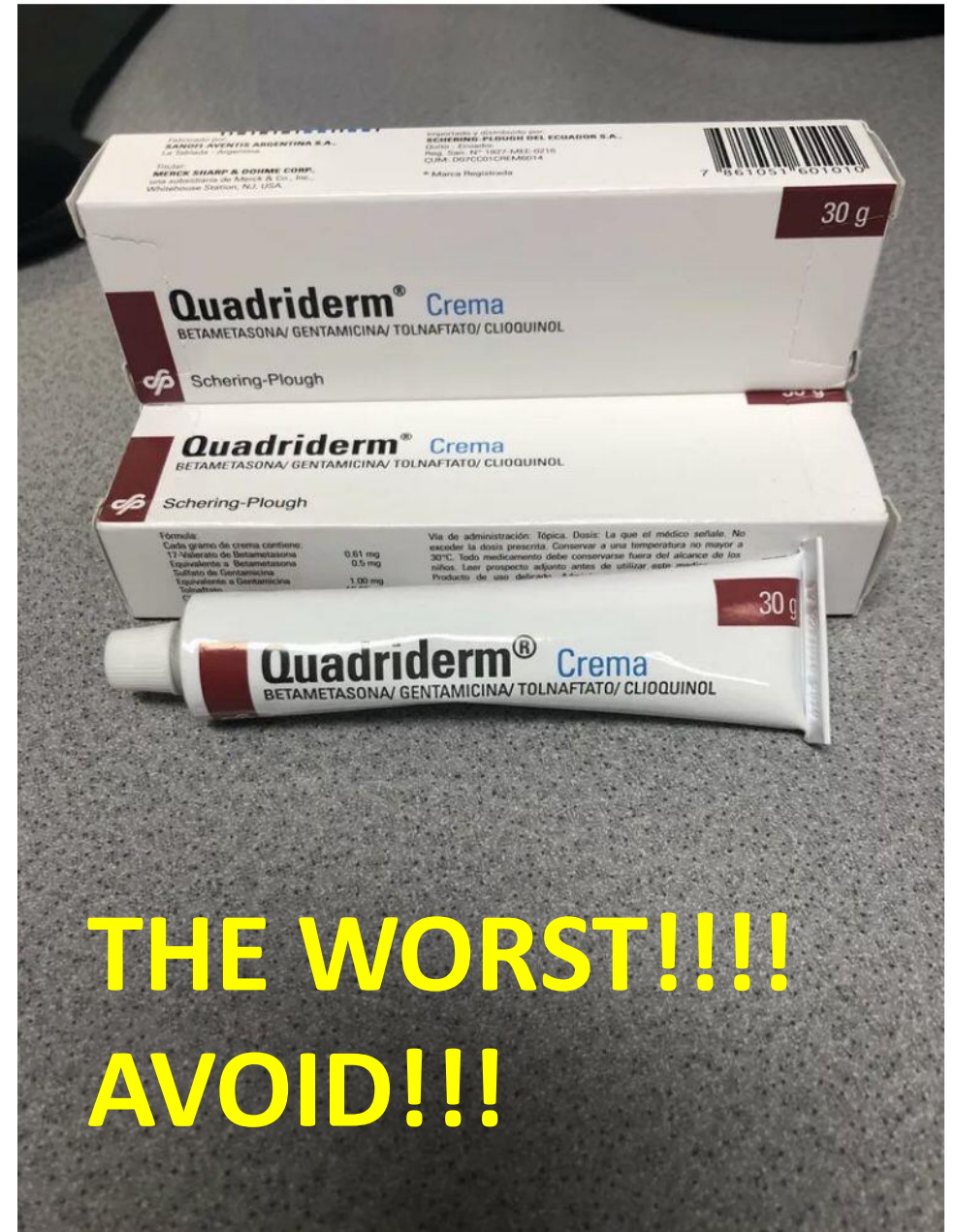
Combination creams

- Preferred by pharmacists
- No purpose
- Makes diagnosis difficult
- Make infective skin conditions worse
- Cortisone causes initial improvement



Combination creams

- Preferred by pharmacists
- No purpose
- Makes diagnosis difficult
- Make infective skin conditions worse
- Cortisone causes initial improvement



Common
conditions occur
commonly

Ringworm

Impetigo

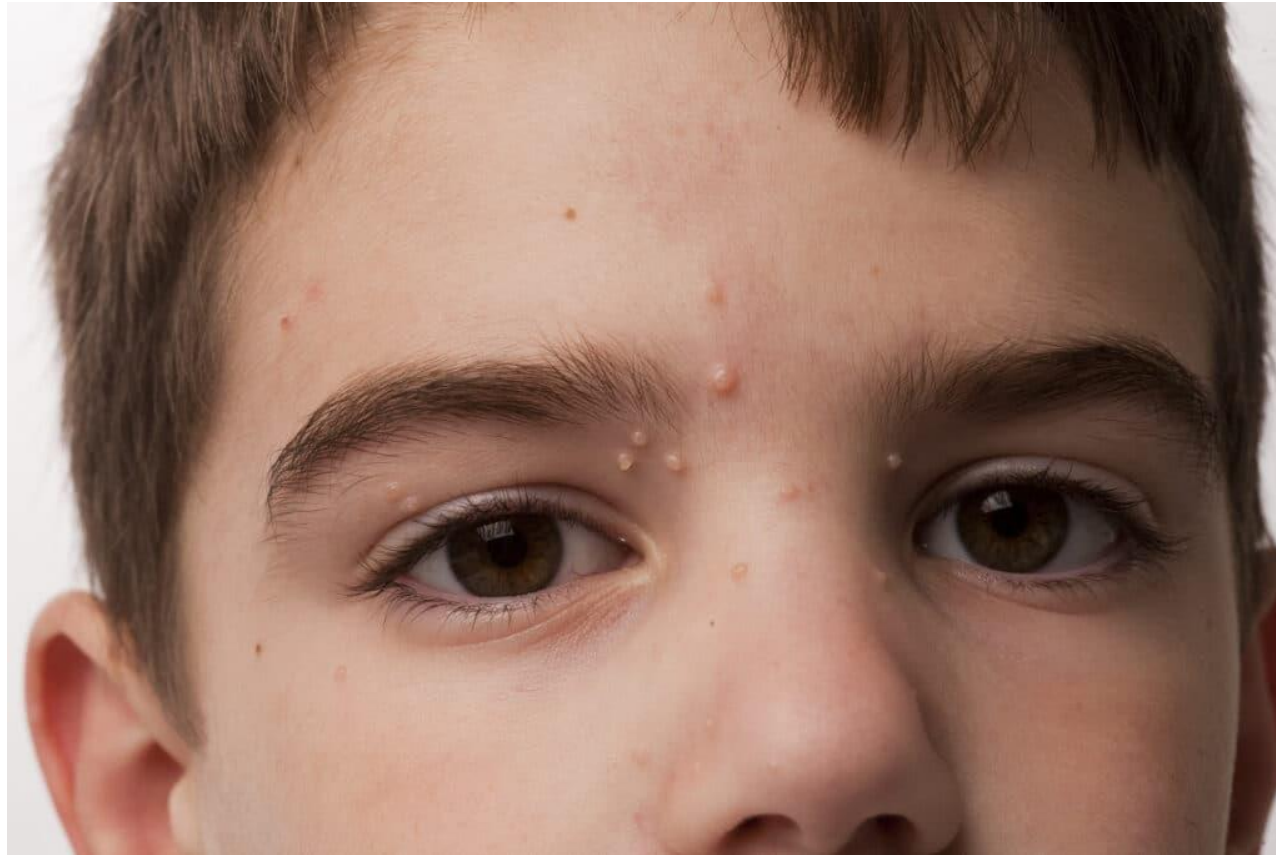Molluscum Contagiosum

Herpes Gladiatorum

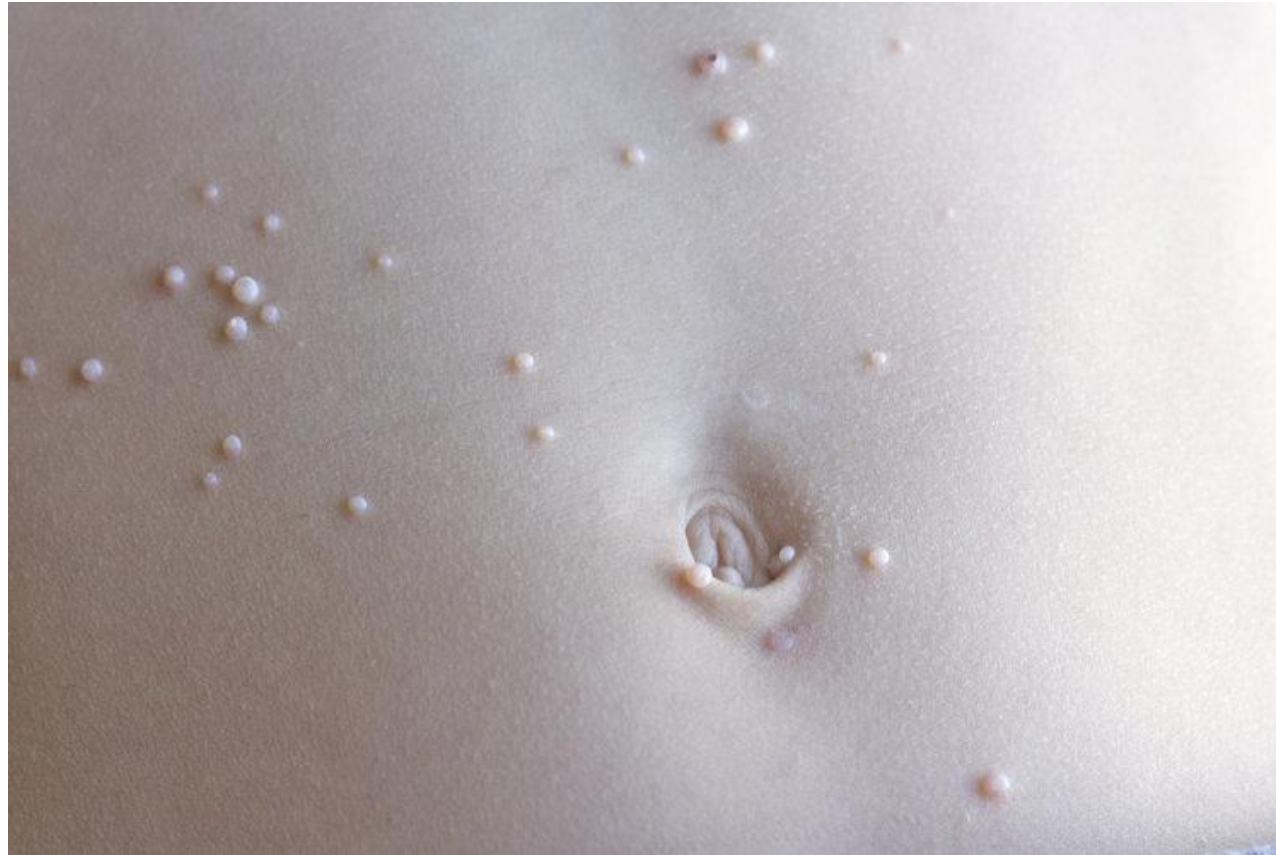Common
conditions occur
commonly

Molluscum Contagiosum

Molluscum Contagiosum

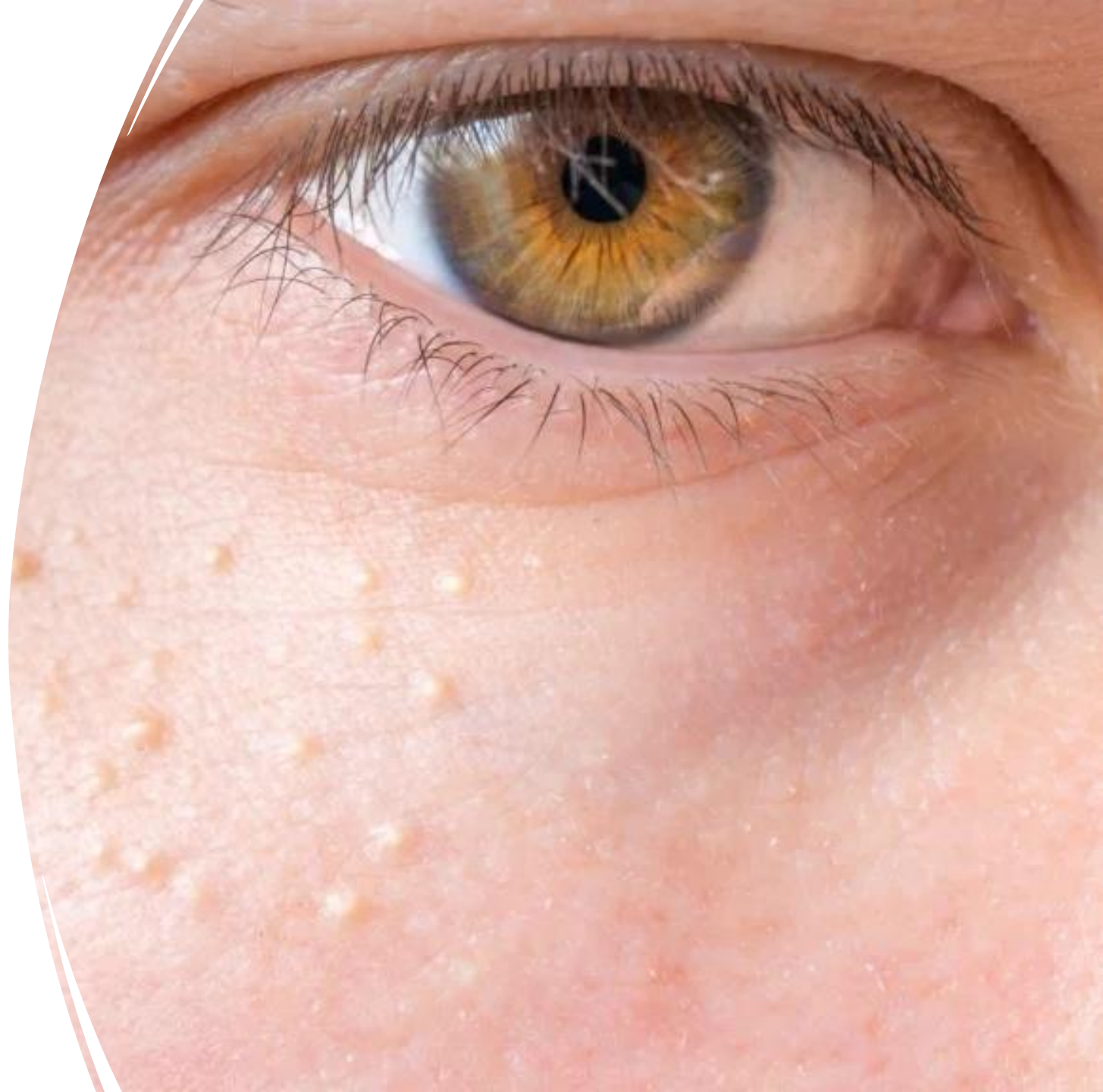

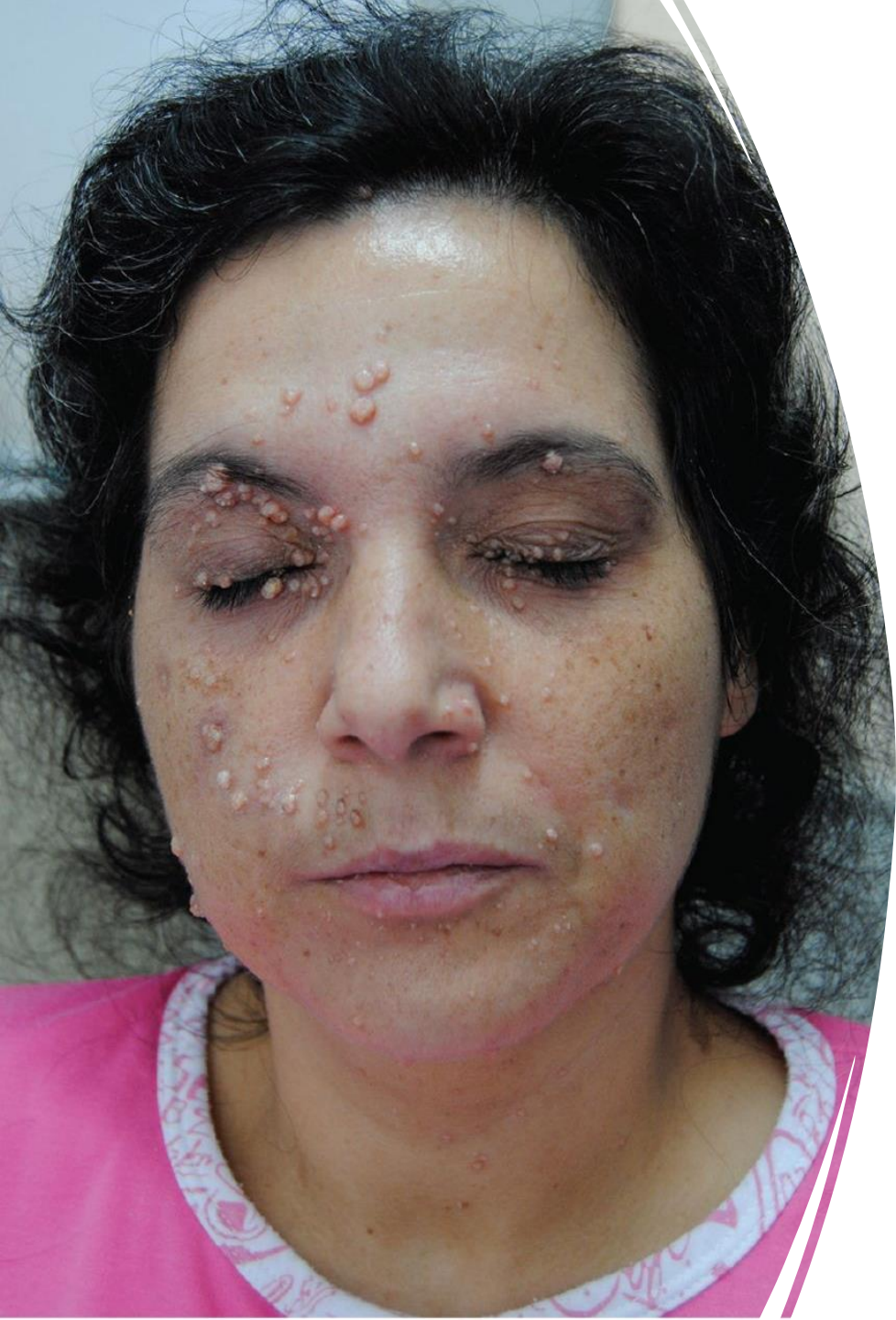Molluscum Contagiosum



Molluscum Contagiosum

- Viral infection
- Very contagious
- Very common
- Children
- Immune system





Molluscum Contagiosum

- Adults???
- Compromised immune system
- HIV, etc.
- Treatment

Common
conditions occur
commonly

Ringworm

Impetigo

Molluscum Contagiosum

Herpes Gladiatorum

Common
conditions occur
commonly

Herpes Gladiatorum

Herpes Gladiatorum

- In about 5% of American wrestlers
- Outbreaks
- South African incidence unknown

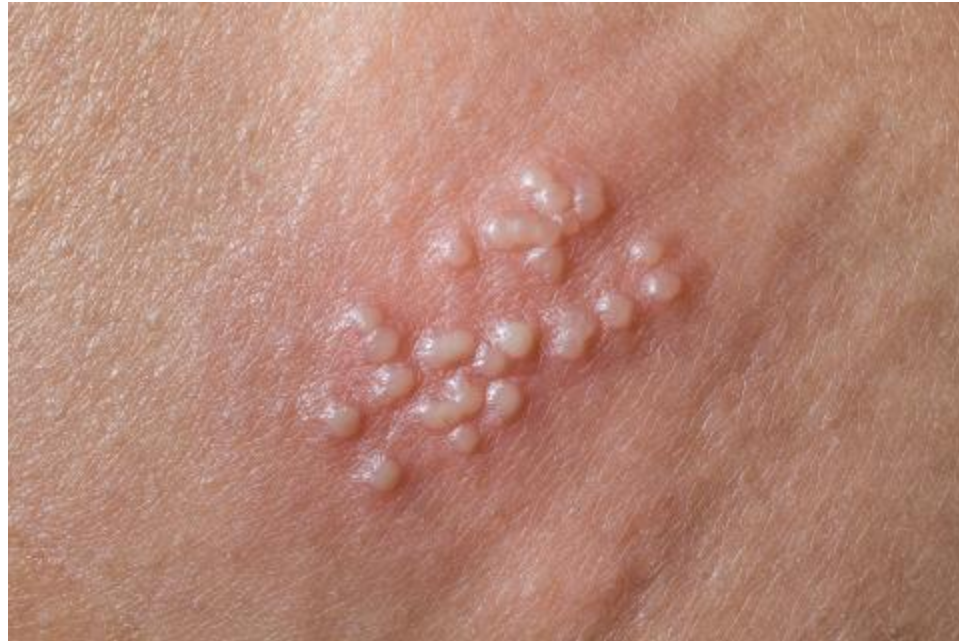- Underdiagnosed,

unrecognized,

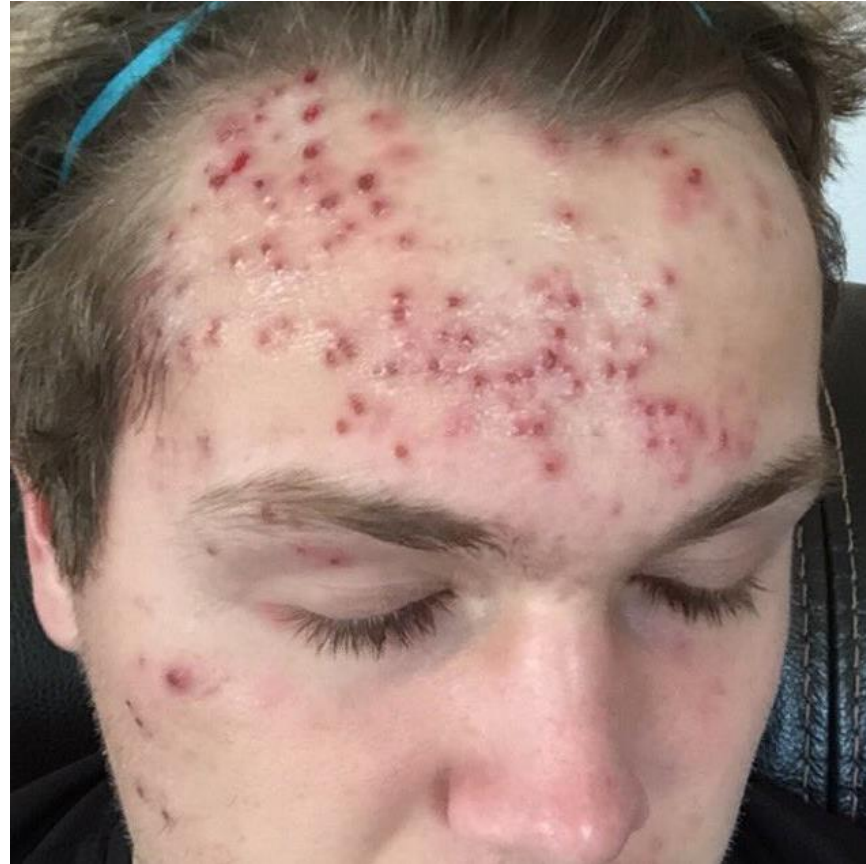underreported?

- *"Herpes is for life"*

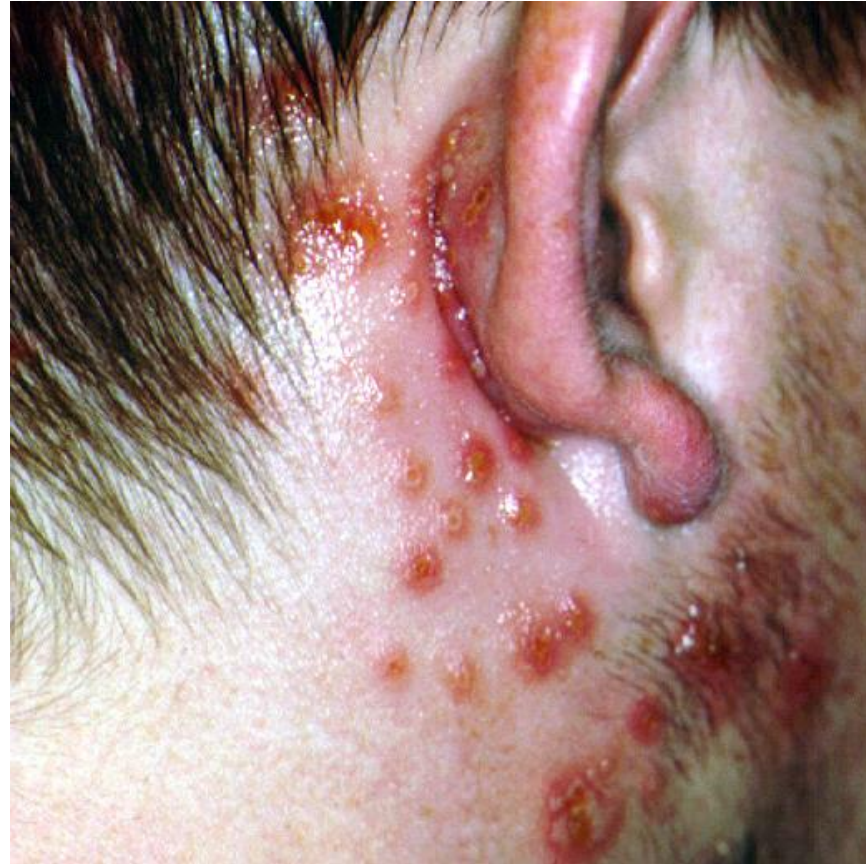Herpes Gladiatorum



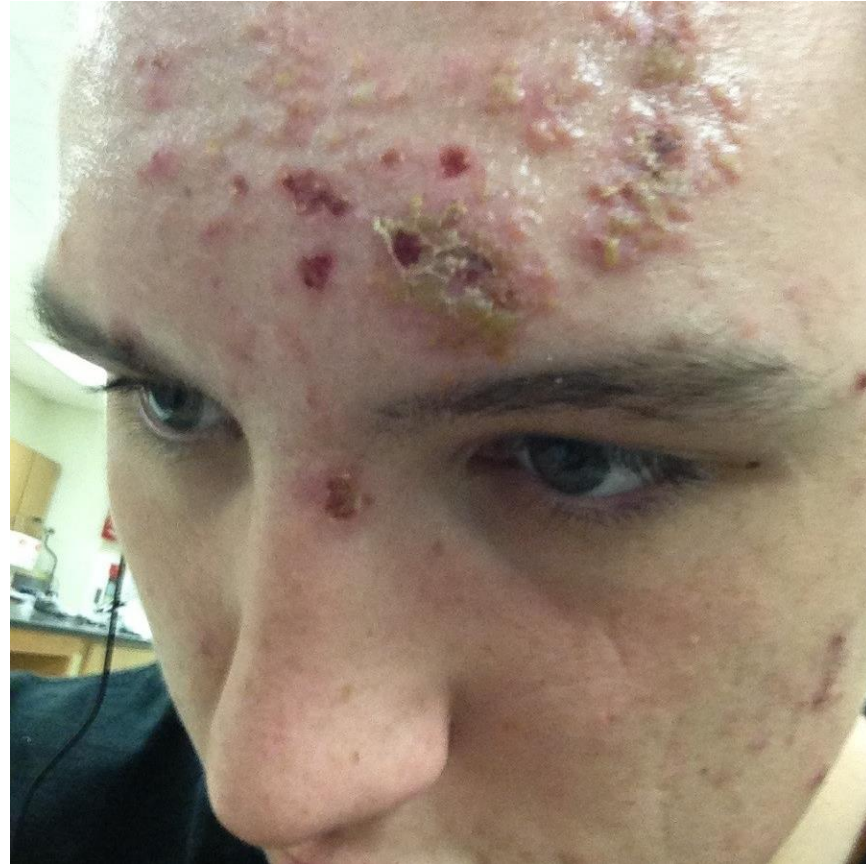Herpes Gladiatorum



Herpes Gladiatorum



Herpes Gladiatorum



Take home message

- We can leave the UV-light
 - Correct treatment
- Keep an eye out for *Herpes Gladiatorum*



QUESTIONS?